

MSK INNERVATIONS

UPPER EXTREMITY

Radial n.	Subscapular n.	Axillary n.
Anconeus	Subscapularis	Deltoid
Brachioradialis	Teres major	Teres minor
Extensor carpi radialis brevis (<i>deep branch of radial</i>)	Musculocutaneous n.	
Extensor carpi radialis longus	Biceps brachii	
Extensor carpi ulnaris (<i>deep branch of radial</i>)	Brachialis	
Extensor digitorum (<i>deep branch of radial</i>)	Coracobrachialis	
Supinator (<i>deep branch of radial</i>)	Posterior interosseus n.	
Triceps	Extensor digiti minimi	
HAND:	Extensor indicis	
Abductor pollicis (<i>deep branch of radial</i>)	Extensor pollicis brevis	
	Extensor pollicis longus	
Median n.	Ulnar n.	
FOREARM:	FOREARM:	
Flexor carpi radialis	Flexor carpi ulnaris	
Flexor digitorum profundus*	1/2 of Flexor digitorum profundus*	
Flexor digitorum superficialis	HAND:	
Flexor pollicis longus	1-3 palmar interosseous (<i>deep branch</i>)	
Palmaris longus	1-4 dorsal interosseous (<i>deep branch</i>)	
Pronator quadratus	Abductor digiti minimi (<i>deep branch</i>)	
Pronator Teres	Abductor pollicis transverse (<i>deep branch</i>)	
HAND:	Adductor pollicis oblique (<i>deep branch</i>)	
Lumbricals 1 & 2 (digits 2 & 3)	Flexor digiti minimi brevis	
Opponens pollicis (<i>recurrent branch</i>)	Lumbricals: 3rd & 4th (<i>deep branch</i>)	
Abductor pollicis brevis (<i>recurrent branch</i>)	Opponens digiti minimi (<i>deep branch</i>)	
Flexor pollicis brevis (<i>recurrent branch</i>)	Palmaris brevis	

BACK (SUPERFICIAL & DEEP)

Spinal accessory n.	Subscapular n.	Suprascapular n.
Trapezius (CN XI)	Teres major	Supraspinatus
Sternocleidomastoid (CN XI)	Subscapularis	Infraspinatus
Ventral primary rami of spinal nn.	Dorsal scapular n.	
Serratus posterior inferior (T9-T12)	Levator scapula	Rhomboid minor
Serratus posterior superior (T1-T4)	Rhomboid major	
Various branches of thoracic & lumbar spinal nn.		
Iliocostalis thoracis (<i>lateral branches of dorsal rami of L & T spinal nn.</i>)		
Iliocostalis (<i>dorsal branches of thoracic nn.; L1, L2, L3 n.</i>)		
Iliocostalis - cervical part - (<i>dorsal branches of thoracic nn.; L1, L2, L3 n.</i>)		

12th intercostal n. & nn. L1-L4	Thoracodorsal n.
Quadratus lumborum	Latissimus dorsi

Dorsal 1 rami of spinal nn.

Longissimus thoracis (C5-T1)	Spinalis cervicis (C2-C6)	Interspinalis thoracis (C7-L5)
Spinalis thoracis (T2-L3)	Semispinalis cervicis (C1-T12)	Interransversarii cervicis posteriores (C1-T1)
Multifidus (C1-L5)	Longissimus capitis	Intertransversarii thoracis (T1-T11)
Semispinalis thoracis (C6-T12)	Longissimus cervicis	Intertransversarii lumborum mediales (L1-L5)
Splenius cervicis (C2-C6)	Iliocostalis - cervical part*	Intertransversarii lumborum lateralis (L1-L5)
Splenius capitis (C3-T6)	Rotatores longi (C1-L5)	Levatores costarum longi (C8-T11)
Semispinalis capitis (C3-T6)	Interspinalis cervicis (C1-C6)	Levatores costarum brevis (C8-T11)

UPPER BODY

ROOT LEVEL	MYOTOME	DERMATOME	DEEP TENDON REFLEX
C3	Neck sidebending	Lateral neck	
C4	Shoulder Elevation	Upper trapezius	
C5	Shoulder abduction	Lateral shoulder	Biceps
C6	Elbow flexion/wrist extension	Dorsum of thumb	Brachioradialis
C7	Elbow extension/wrist flexion	Dorsum mid finger	Triceps
C8	Thumb extension	Ulnar border of hand	
T1	Finger abduction/adduction	Medial brachium	

LOWER BODY

ROOT LEVEL	MYOTOME	DERMATOME	DEEP TENDON REFLEX
L1		Groin	
L2	Hip flexion (iliopsoas)	Anterior mid thigh	
L3	Knee extension (quadriceps)	Medial knee	
L4	Ankle dorsiflexion/inversion	Medial leg	Patellar
L5	Big toe extension	Dorsum of foot	
S1	Ankle eversion	Lateral foot	Achilles
S2-4	Bladder & intrinsics of foot	Concentric rings around anus	

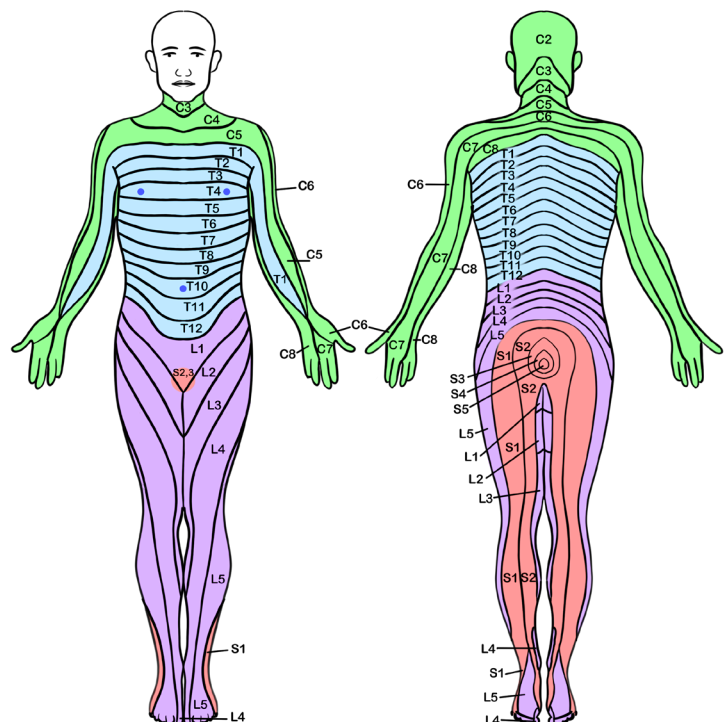
LOWER EXTREMITY

Femoral n.	Tibial n.	Obturator n.
Articularis genus	Biceps femoris long head	Adductor brevis
Iliacus	Flexor digitorum longus	Adductor longus
Pectineus*	Flexor hallucis longus	Adductor magnus*
Rectus Femoris	Gastrocnemius	Adductor minimus
Sartorius	Plantaris	Gracilis
Vastus intermedius	Popliteus	Obturator externus
Vastus lateralis	Semimembranosus	Obturator Internus n.
Vastus medialis	Semitendinosus	Obturator internus
	Soleus	Superior gemellus
	Tibialis posterior	
Common Fibular n.	Superior gluteal n.	Quadratus Femoris n.
Biceps femoris short head	Gluteus medius	Inferior gemellus
Superficial Fibular n.	Gluteus minimus	Quadratus femoris
Peroneus brevis	IT tract/band	Deep sacral plexus branches (L5-S1) & ventral rami (S1-S2)
Peroneus longus	Tensor fascia lata	Piriformis
Deep Fibular n.	Inferior gluteal n.	Medial plantar n.
Extensor digitorum longus (L5-S1)	Gluteus maximus	1st lumbrical
Extensor digitorum brevis (L4-S1)		Abductor hallucis
Extensor hallucis brevis (L5-S1)		Flexor digitorum brevis
Extensor hallucis longus (L5)	Ventral 1° Rami	Flexor hallucis brevis*
Peroneus tertius (L5-S1)	Psoas major	
Tibialis anterior	Psoas minor	
Lateral plantar n.		
1-3 plantar interosseous	Adductor hallucis transverse head	Lumbricals 2-4
1-4 dorsal interosseus	Flexor digiti minimi brevis	Opponens digiti minimi
Abductor digiti minimi	Flexor hallucis brevis*	Quadratus plantae
Adductor hallucis oblique head		

THORAX

Intercostal nn.	Iliohypogastric	Ilioinguinal n.
External oblique*	External oblique*	External oblique*
Internal oblique*	Internal oblique*	Internal oblique*
Transversus abdominus*	Transversus abdominus*	Transversus abdominus*
Long thoracic n.	Phrenic n.	Ant. cutaneous intercostal n.
Serratus anterior	Diaphragm	Rectus abdominus
Medial pectoral n.	Lateral pectoral n.	
Pectoralis major	Pectoralis major	
Pectoralis minor	Pectoralis minor	

DERMATOMAL MAP



* = More than one innervation

WWW.STRENGTHRESURGENCE.COM